

## TIMELINE

## What's new with the amnesic patient H.M.?

Suzanne Corkin

H.M. became amnesic in 1953. Since that time, nearly 100 investigators, first at the Montreal Neurological Institute and since 1966 at the Massachusetts Institute of Technology, have participated in studying him. We all understand the rare opportunity we have had to work with him, and we are grateful for his dedication to research. He has taught us a great deal about the cognitive and neural organization of memory. We are in his debt.

Almost 50 years have elapsed since the neurosurgeon William Beecher Scoville resected H.M.'s medial temporal lobe (MTL) structures for the relief of medically intractable epilepsy (TIMELINE). The aetiology of H.M.'s epilepsy is unclear, because he has a family history of epilepsy (three first cousins on his father's side of the family) and he sustained a head injury with unconsciousness at age nine. The outcome of Scoville's radical, experimental operation was twofold: H.M.'s seizures decreased markedly in frequency to the point that, at present, he has at most two major seizures a year; and he immediately showed a severe anterograde amnesia that has persisted. H.M.'s rise to fame began in 1957 with the publication of Scoville and Milner's<sup>1</sup> paper in the *Journal of Neurology, Neurosurgery, and Psychiatry*: 'Loss of recent memory after bilateral hippocampal lesions'. This paper has been cited 1,744 times since its publication in 1957, and is on a par with the 1998 paper by Gage and colleagues<sup>2</sup>, 'Neurogenesis in the adult human hippocampus', one of the most highly cited articles in the field. Gage's paper has had 282 citations since

its November 1998 publication, whereas Scoville and Milner's paper has had 258 citations since that date, attesting to the latter's long-lasting prominence and influence. Scoville and Milner's title reflected their belief that the lesion of the hippocampus, as opposed to the other structures that were excised, was the culprit behind H.M.'s amnesia, and they concluded that the severity of amnesia is related to the size of the hippocampal removal. This view, which was unchallenged for decades, derived, in part, from converging evidence from two other cases that were described by Penfield and Milner<sup>3</sup>. Both of their patients became amnesic after a left temporal lobectomy that included a large hippocampal removal, and both showed concomitant electrographic abnormality in the right MTL, indicating that, like H.M.'s, their amnesia resulted from a bilateral lesion. This hypothesis was confirmed in one of the patients who later came to autopsy<sup>4</sup>.

The goals of this article are to provide a brief overview of published results obtained with H.M. over several decades, to present some new data on putative information storage in extrahippocampal sites, and to consider the effect that H.M.'s condition has on his personal identity.

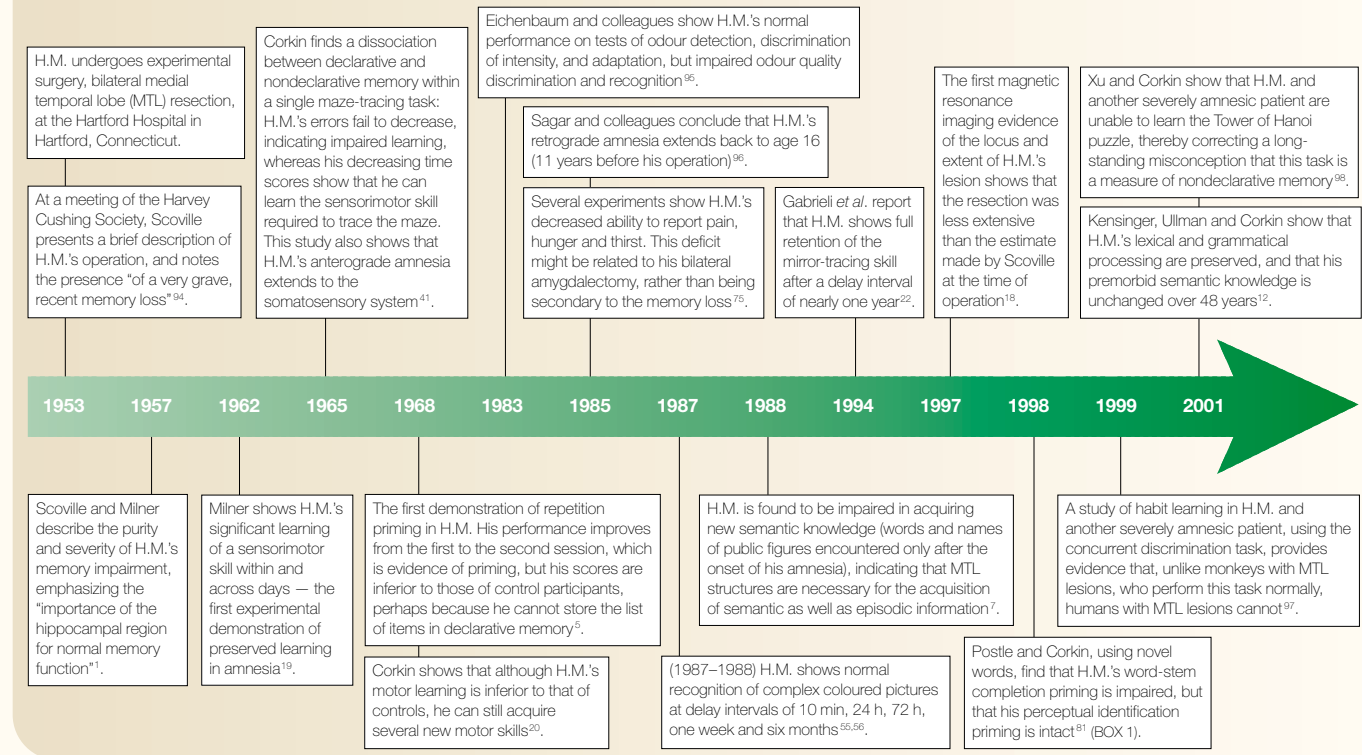
### Early discoveries

The initial question addressed by Milner and her students was whether H.M.'s anterograde amnesia was global: that is, whether he was severely impaired regardless of the kind of memory test (free recall, cued recall, yes/no recognition, multiple-choice recognition,

learning to criterion); regardless of the kind of stimulus material (words, digits, paragraphs, pseudowords, faces, shapes, clicks, tones, tunes, sounds, mazes, public events, personal events); and regardless of the sensory modality through which information was presented (vision, audition, somatosensory system, olfaction). The answer to these questions, on the basis of decades of experiments, is 'yes': his impairment is not only severe, but also pervasive<sup>5,6</sup>. H.M.'s anterograde amnesia manifests as deficient acquisition of episodic knowledge (memory for events that have a specific spatial and temporal context) and of semantic knowledge (general knowledge about the world, including new word meanings). The evidence strongly supports the conclusion that the MTL structures that were removed in H.M. are crucial for long-term declarative memory (conscious recollection of facts and events), including the acquisition of new semantic knowledge<sup>7</sup>. Other studies indicate that H.M.'s short-term memory is intact and, therefore, not dependent on these MTL structures<sup>8-11</sup>. So, he can encode new information, but rarely uses this information to establish a long-term trace.

H.M.'s memory and language capacities are dissociable. In 1968, Milner, Corkin and Teuber<sup>5</sup> noted that, "His comprehension of language is undisturbed: he can repeat and transform sentences with complex syntax, and he gets the point of jokes, including those turning on semantic ambiguity." A 'mild language disorder' that was described later<sup>6</sup> might have preceded the brain operation, and could be related to substandard education and a low socioeconomic background<sup>12</sup>. A recent study<sup>12</sup> underscores the relative integrity of H.M.'s language capacities. Extensive analysis of his lexical memory and grammatical processing found normal performance relative to age- and education-matched control participants, with the one exception being his performance on fluency tasks (see also REF. 13). In addition, longitudinal data collected over 48 years (1953-2000) showed no evidence of a significant change in his scores on four

Timeline | Scientific landmarks in the study of H.M.



Wechsler subtests (Information, Comprehension, Similarities and Vocabulary), and no evidence of a lexical memory impairment<sup>12</sup>. Other investigators<sup>14–17</sup> have argued that H.M.'s subtle deficits in language comprehension and production are a consequence of his MTL lesion. This explanation seems unlikely, because amnesic patients with lesions restricted to the hippocampal formation are unimpaired on these kinds of task<sup>13</sup>. Furthermore, amnesic patients in whom semantic knowledge is impaired have lesions of lateral temporal neocortex in addition to the MTL lesion; the extent of impairment is related to the extent of damage to lateral temporal cortex. It is possible that H.M. has some minimal damage to lateral temporal neocortex that could have contributed to his subtle deficits<sup>18</sup>.

**Residual learning capacities**

The dissociation in H.M. between the acquisition of declarative memory and other kinds of learning was initially shown for motor learning. The first experimental demonstration of preserved learning in amnesia was Milner's report that H.M.'s time and error scores decreased within and across three days of training on a mirror-tracing task<sup>19</sup>. H.M. was asked to draw a line between two adjacent outlines of a star-shaped pattern, but he could see only his hand, the pencil and the star reflected in a mirror (with left and right reversed).

Although no control data were reported, he showed clear skill learning, in marked contrast to the absence of declarative memory for any details of the testing sessions, or even a feeling of familiarity. Subsequent studies, which included healthy volunteers, showed that his initial performance on motor learning tasks was inferior to those of control participants, but that he could still show consistent improvement over several consecutive days of testing<sup>20,21</sup>, and that he could retain that nondeclarative knowledge for as long as a year<sup>22</sup>. These results indicate that acquisition and retention of a visuomotor skill rely on substrates beyond the MTL region. (H.M.'s motor

performance has always been slow relative to control participants; this disturbance in movement rate is probably related to the marked and diffuse atrophy of his cerebellar vermis and hemispheres, a well-documented side effect of taking the antiepileptic drug phenytoin (*Dilantin*). Cerebellar signs are typically not seen in other amnesic patients.)

Other kinds of learning are preserved in H.M., and are also believed to be independent of the MTL memory system. These include perceptual aftereffects<sup>23</sup>, prism adaptation (R. Held, unpublished data; H. C. Mapstone and S. C., unpublished data), perceptual learning (reading mirror-reversed words<sup>24</sup>),

Table 1 | Normal and impaired repetition priming in H.M.

Normal	Impaired
Patterns <sup>87</sup>	Incomplete pictures <sup>5,77*</sup>
Word-stem completion with familiar words <sup>77,81</sup>	Word-stem completion with novel words <sup>81</sup>
Category exemplar production (M. M. Keane <i>et al.</i> , unpublished data)	Category decision (M. M. Keane <i>et al.</i> , unpublished data)
Word-fragment completion <sup>88</sup>	Lexical decision <sup>89</sup>
Homophone spelling <sup>90</sup>	
Perceptual identification of familiar words <sup>25,81</sup>	
Perceptual identification of pseudowords <sup>25</sup>	
Perceptual identification of novel words <sup>81</sup>	

\*H.M.'s impairment on this task might be related to its having a declarative memory component<sup>91</sup>. Other laboratories have reported normal category decision priming and lexical decision priming in amnesia<sup>92,93</sup>. It is, therefore, possible that H.M.'s impairment is idiosyncratic.

and most kinds of repetition priming (TABLE 1). Repetition priming occurs incidentally when stimuli encountered in a study list influence performance on a subsequent test, without conscious awareness of that influence. For example, deciding whether the word 'episode' in a study list is something you can or cannot touch will increase the likelihood that in the subsequent test, you will complete the stem 'epi-' as 'episode' (the primed word) rather than as 'epic', 'epicure' or 'epilepsy' (unprimed words). Experiments show that the kinds of priming that are normal in H.M. are mediated by at least two dissociable priming processes: a visuo-perceptual (pre-semantic) process, for which the neural substrate is the cortical areas that receive and process sensory input; and a conceptual process, for which the neural substrate is probably polymodal areas in frontal, temporal and parietal cortices<sup>25</sup>. These brain areas are spared in H.M. and presumably support normal priming independently of the damaged MTL memory system. Although H.M. typically performs perceptual and conceptual priming tasks normally, one study found a clear-cut dissociation in H.M. between perceptual and conceptual priming with novel words (BOX 1). The design of our priming experiments was such that each priming test was paired with a recognition memory test using the same or similar stimuli. On these declarative memory tests, in which H.M. was instructed explicitly to remember and then recall or recognize the words, he was impaired across the board. This result is consistent with his global amnesia.

### Storage in extrahippocampal sites

Recent investigations have questioned the importance of the hippocampus for episodic memory, and instead attribute greater significance to structures within the parahippocampal region<sup>26,27</sup>, particularly for visual recognition memory<sup>28–31</sup>, spatial memory<sup>32,33</sup> and semantic memory<sup>34</sup>. This view assumes that different MTL structures act independently, and it heightens interest about the possible contributions of H.M.'s preserved MTL structures<sup>18</sup> (for example, caudal perirhinal and parahippocampal cortices; FIG. 1). New evidence of neurogenesis in the adult human hippocampus<sup>2</sup> makes this possibility even more plausible than it was a few years ago. Several pieces of data indicate what these contributions might be.

In April 1958, five years after his operation, H.M. and his parents moved to an 860-sq ft bungalow near Hartford, Connecticut. In 1966, during a visit to the Massachusetts Institute of Technology (MIT) Clinical Research Center, H.M. was able to draw an

accurate floor plan of his home from memory (FIG. 2a). After his father died, H.M. and his mother remained in that house until 1974, when they went to live with a relative who was a psychiatric nurse and could care for them in her home. Three years later (24 years after his operation), when H.M. was again visiting

MIT, I asked him where he lived, and he gave me his former address. I then asked him to draw a floor plan of that house (FIG. 2b). I showed this drawing to his caregiver, who was familiar with the layout of the house; she verified that he had included all the rooms in their proper location. Just to be sure, I recently

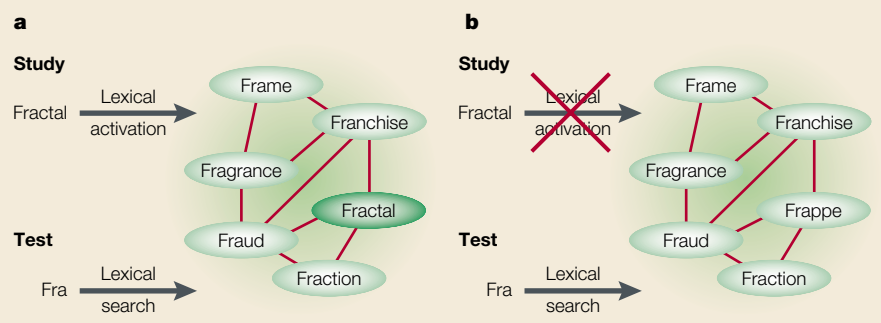
### Box 1 | The granola-jacuzzi experiment

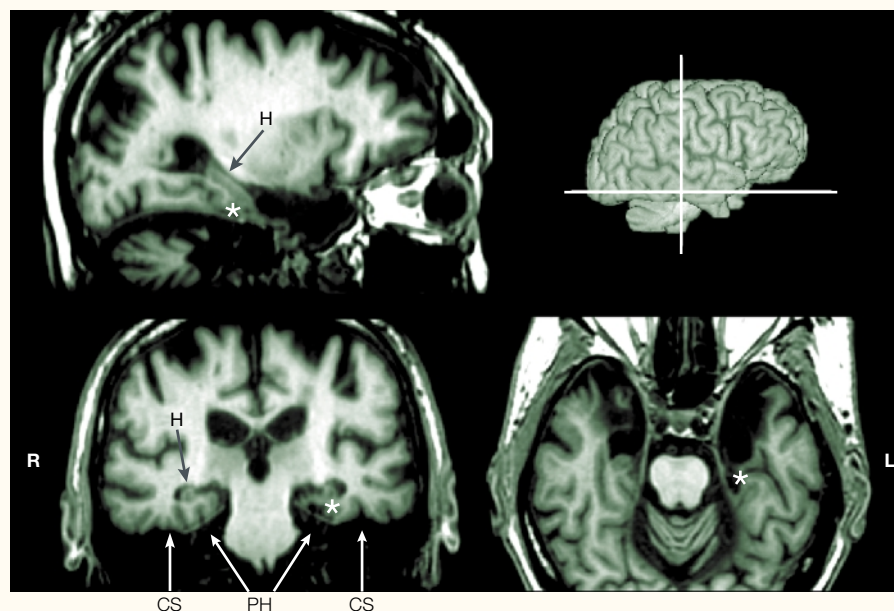
Knowing that H.M. showed normal word-stem completion priming with words that entered the dictionary before his operation<sup>25,77</sup>, Bradley Postle and I were curious to know whether he would also show priming with words that entered the dictionary after 1965 (12 years after his operation and the onset of his anterograde amnesia). His task was to read words aloud as they were presented, one by one, on a computer screen. One minute later, he viewed three-letter stems, half corresponding to words in the study list and half corresponding to unstudied words, and was asked to complete each stem with the first word that came to mind. The measure of priming was the number of words completed to studied words minus the baseline score of stems completed to unstudied words. We predicted that he would be impaired on this test relative to age- and education-matched control subjects because he lacked representations in his lexicon of post-1965 words<sup>78–80</sup>. As a result, there would be no traces to activate (or prime) during the study phase of the repetition priming test, and so he would complete word stems to words that he had acquired preoperatively. That is exactly what we found<sup>81</sup>. Not only was H.M. impaired on the repetition priming task with postmorbidity words, he also was impaired (as expected) on explicit measures of word knowledge; specifically, on cued recall of the words, generation of definitions and recognition of definitions. (As in previous studies, he primed normally with premorbidity words, but could not recall or recognize them explicitly.)

The proposed model for word-stem completion priming requires that pre-existing lexical representations of the studied words be activated during the study phase to bias the lexical search during the test. Biasing the search increases the probability that studied words will be retrieved (a). If lexical representations for the studied words do not exist, as was the case with post-1965 words for H.M., trace activation cannot occur, and the studied words will not be retrieved during the test (b).

A different mechanism is believed to support perceptual identification priming, on which H.M. showed normal performance for premorbidity and postmorbidity words. The procedure during the study condition was similar to that used for word-stem completion priming, the difference being that the exposure duration was shorter. H.M. viewed a list of words that were flashed on the screen, and was asked simply to read the words aloud. The exposure duration was set so that he achieved ~50% correct responses. During the test, he read the studied words again, intermingled with unstudied words. The measure of priming was the number of studied words correctly identified minus the number of unstudied words correctly identified. H.M. identified more studied than unstudied words, and, in contrast to word-stem completion priming, his performance was identical for premorbidity and postmorbidity words. Thus, the manipulation of premorbidity versus postmorbidity words did not affect his performance.

Evidence from previous studies indicates that word-stem completion priming is localized to perisylvian areas of the left (language-dominant) hemisphere, whereas perceptual identification priming is localized to areas in the ventral visual stream<sup>25,82–84</sup>. These areas are preserved in H.M., except for minimal damage to anterolateral temporal cortex<sup>18</sup>. His impaired word-stem completion priming with novel words is related to his medial temporal lobe lesion and resulting anterograde amnesia. Specifically, after 1953, he was unable to acquire new vocabulary words<sup>7</sup>, and therefore lacked the representations to support lexical retrieval procedures.





**Figure 1 | Multiplanar views of 18 averaged T1-weighted MRI volumes showing preserved structures in H.M.'s MTL.** This magnetic resonance imaging (MRI) scan was obtained on 15 December 1998 (slice thickness: 1.00 mm; PixDim x: 0.976562 mm; PixDim y: 0.976562 mm). The images are based on data averaged over 18 runs; images were motion corrected using the first scan (out of the 18 axials) as a reference. The asterisk marks the intersection of the three viewing planes, just caudal to the left medial temporal lobe (MTL) resection, seen best in the transaxial view. Top left, sagittal view; bottom left, coronal view; bottom right, transaxial view; top right, surface rendering showing locations of transaxial and coronal planes. Abbreviations: CS, collateral sulcus; EC, entorhinal cortex; H, hippocampus; L, left; PH, parahippocampal gyrus; R, right.

asked the current resident of the house if he would provide me with a floor plan (FIG. 2c). The similarity between H.M.'s drawings and the current floor plan indicates that H.M.'s topographical memory for the house that he had never seen before the onset of his amnesia, but where he lived after his operation, is intact. Because he could recall the correct address when asked where he lived, it seems that it is not simply the spatial content of the information that makes it memorable for him. Rather, it is the broader domain of personal semantic memory that is favoured by virtue of the information's being learned slowly over an extended period of time, presumably with the support of cortical structures<sup>35</sup>. This knowledge is in marked contrast to H.M.'s striking inability to incorporate other new information into declarative memory. At the same time, it raises the possibility that he might have been able to acquire new vocabulary words if daily training had been carried out over a period of years<sup>7</sup>.

Preserved topographical memory in amnesia has been described in single case reports<sup>36,37</sup> (see also REF. 38 for a case of preserved topographical memory in Pick's disease). Both patients had large bilateral MTL lesions, but were still able to perform several challenging cognitive map tests normally. The test items

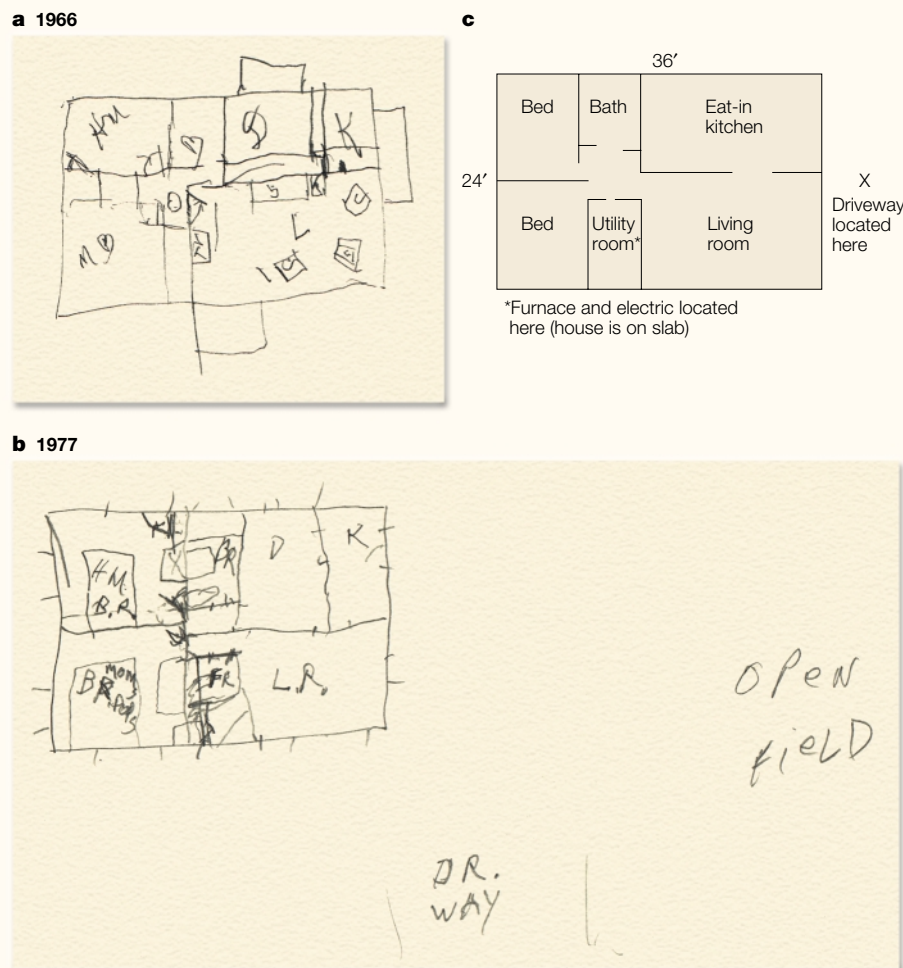
focused on spatial representations that were acquired premorbidly; specifically, the neighbourhood or region in which each patient had grown up. By contrast, both patients were unable to acquire new spatial memories. What is so remarkable about H.M.'s ability to draw an accurate floor plan of his home is that, unlike these cases<sup>36,37</sup>, H.M. acquired the representation after the onset of his amnesia. Presumably, he was able to construct a cognitive map<sup>39</sup> of the spatial layout of his house as the result of daily locomotion from room to room, thereby encoding the location of each room in relation to the other rooms. This allocentric representation of his house, based on thousands of 'learning trials', was shown in his drawing of the floor plan. His ability to recall

**“What is so remarkable about H.M.'s ability to draw an accurate floor plan of his home is that ... [he] acquired the representation after the onset of his amnesia.”**

material encountered after 1953 contrasts sharply with his impaired performance on all other recall tests. In particular, he is severely impaired on other spatial memory tasks, including the acquisition of the correct sequence of turns in a visual<sup>40</sup> and a tactile<sup>41</sup> stylus maze. It is important to note, however, that on learning tasks performed in the laboratory, H.M. never had an opportunity for exhaustive and long-term repetition comparable to repeated locomotion through his house.

What anatomical considerations would explain the selective sparing of H.M.'s ability to acquire a topographical representation of the rooms in his house? Lesion studies provide some clues. Loss of topographical familiarity is a selective “inability to match the perceived environment with stored memories that would allow the surroundings to be recognized”<sup>42</sup>. This disorder is associated with bilateral posterior cerebral lesions or unilateral posteromedial lesions in the left or right hemisphere<sup>42–44</sup>. Topographical disorientation has also been reported after left or right temporal lobectomy and after damage to right retrosplenial cortex<sup>45,46</sup>. More precise anatomical correlates come from functional imaging studies that have identified a network of brain regions that supports topographical memory: medial parietal lobe, posterior cingulate gyrus, occipitotemporal areas, parahippocampal gyrus, right hippocampus and right retrosplenial cortex<sup>46–51</sup>. These structures are included in the components of an allocentric coordinate system proposed by McNaughton *et al.*<sup>52</sup> (FIG. 3). The regions shown in green (the six at the top) are preserved in H.M., whereas the structures shown in red were excised (the three at the bottom). Thus, H.M. has some of the components of this spatial processing network, and they probably contribute to his ability to draw a floor plan of his former house. In addition, the spared posterior 2 cm of his parahippocampal gyrus could have been important, because the parahippocampal cortex receives spatial information directly from posterior parietal cortex and indirectly through the retrosplenial cortex<sup>53</sup>. Furthermore, a lesion study in humans has implicated the right parahippocampal cortex as a substrate for spatial memory<sup>54</sup>.

We uncovered another instance of atypical declarative memory performance in H.M. in a study of complex picture recognition<sup>55,56</sup>. He studied coloured magazine pictures, each for 20 s, and subsequently showed normal recognition at 10 min, 24 h, 72 h, one week and six months, relative to control participants (who viewed each picture for 1 s). A reasonable explanation for his success is that his responses were based on familiarity judgements, rather than conscious recollection<sup>57,58</sup>. Recently,



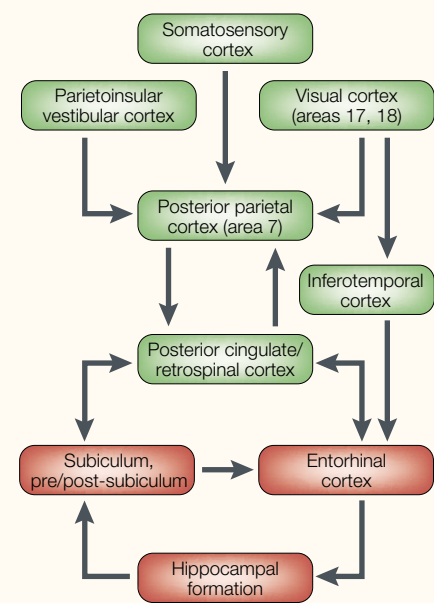
**Figure 2 | Evidence of postmorbidity acquisition of semantic knowledge.** **a** | H.M.'s 1966 drawing of the floor plan of the house where he lived from 1958 (five years after his operation) to 1974. **b** | H.M.'s 1977 drawing of the floor plan of the same house, three years after he moved to another residence. **c** | Current floor plan of the house. The wall between the kitchen and dining room was taken down by a recent owner to make an eat-in kitchen. Abbreviations in **a**: B, bathroom; C, chair; D, dining room; HM, H.M.'s room; K, kitchen; L, living room; MB, Mom's bedroom; TV, television. Abbreviations in **b**: BR, bathroom; D, dining room; FR, furnace room; H.M. B.R., H.M.'s bedroom; K, kitchen; L.R., living room; Mom & Dad's B.R., Mom and Dad's bedroom.

investigators have argued that these two kinds of recognition represent two distinct processes, supported by different neural substrates. One hypothesis is that conscious recollection of the learning episode depends on the hippocampus, whereas familiarity judgements without episodic content rely on perirhinal cortex<sup>28,59,60</sup>. H.M. does have some residual ventral perirhinal cortex that theoretically could support performance on certain tests of recognition memory and cued recall. Consistent with this interpretation is the report that an amnesic patient with extensive damage to MTL structures (including perirhinal cortex, amygdala, hippocampal formation and parahippocampal cortex) does not show the benefit of extended study of pictures<sup>61</sup>.

In everyday life, H.M. occasionally shows some recognition ability. For example, in

1992, when I asked him who the president of the United States was, he could not recall the president's name. When I prompted him by telling him that his initials were G.B. and then that his first name was George, he still could not give the correct name. Finally, when I gave him a three-alternative forced choice of George Burns, George Brown and George Bush, H.M. answered correctly (BOX 2).

One way to illustrate the functional potential of H.M.'s preserved MTL tissue would be to show task-related activation with functional magnetic resonance imaging (fMRI). To this end, H.M. and control participants viewed complex coloured magazine pictures, each for 3 s (encoding runs). Like the control participants, H.M. showed a small area of significant activation in the caudal MTL (FIG. 4). This activation seems to be task related (see



**Figure 3 | Spatial processing network proposed by McNaughton *et al.*** Structures highlighted in green are preserved in H.M.; structures highlighted in red are damaged. The green structures, together with the caudal parahippocampal gyrus (not shown here), represent the proposed substrate for H.M.'s ability to draw a floor plan of the house where he lived after the onset of his severe amnesia. Modified with permission from REF. 52 © 1991 Massachusetts Institute of Technology.

time course) and is consistent with other reports of MTL activation during encoding of visual stimuli<sup>62–64</sup>.

**Does H.M. have a sense of self?**

Philosophers, psychologists and neuroscientists have proposed that, without memory, a person lacks an identity — a sense of self. By this view, H.M. should not have a sense of who he is. The following observations are worthy of consideration in this regard. Amnesia is not an all-or-nothing condition, and even H.M., from time to time, has meagre conscious recollections of information encountered postoperatively<sup>6</sup>. In addition, he has memories of his childhood, which include vacations with his parents and information about a number of relatives, although these memories seem to be semanticized<sup>65</sup>. For example, in trying to elicit an autobiographical memory, I asked him, “What is your favourite memory that you have of your mother?” “Well I, that she’s just my mother.” “But can you remember any particular event that was special — like a holiday, Christmas, birthday, Easter?” “There I have an argument with myself about Christmas time.” “What about Christmas?” “Well, ’cause my daddy was from the South,

Box 2 | Famous Faces Test II

When H.M. correctly chose George Bush's name from three alternatives, he could simply have guessed the answer by chance. To be convinced that he can acquire at least a modicum of new semantic knowledge, one would like to see accurate responses to multiple test items. Elizabeth Kensinger and I gleaned this kind of evidence from his performance on the Famous Faces Test II<sup>85</sup>. In March 2000, H.M. viewed photographs of people who were famous at some point between the 1920s and the 1980s. We asked him to name each individual, the decade in which they were famous and the reason for their fame. He performed marginally better than healthy volunteers ( $P < 0.1$ ) on faces from the 1920s and 1930s (perhaps because of a lack of retroactive interference), but was significantly worse than volunteers from the 1950s onwards. We separated items into those that were 'easy' or 'hard' for volunteers (above or below the median of the healthy volunteers' mean<sup>86</sup>) to determine whether H.M. showed selective forgetting of 'hard' items. He retrieved 'easy' and 'hard' faces from the 1920s to the 1950s. By contrast, for the 1960s onwards, the two items he retrieved were both 'easy' items: he named (without cues) John F. Kennedy (whom he knew was a president, and believed was assassinated) and Ronald Reagan (whom he said was an actor, and, when asked for more information, said he thought was a president).

In a second run through the series of faces that H.M. had not been able to name, we provided him with four semantic cues for each individual (for example, for Mao Tse-Tung: he was a leader in China). The semantic cues did not elicit any further correct responses. We then gave him phonemic cues, one at a time (the person's initials, the first syllable of the first name, all of the first name, the first syllable of the last name, all of the last name; see table). Using phonemic cues, given while he viewed the photograph, he named 18 out of 36 individuals, but was unable to give the correct decade or reason for their fame. These results indicate that H.M.'s public semantic knowledge, although inferior to that of control participants, does include some information from the decades after the onset of his amnesia. Nevertheless, the traces of information that are stored in H.M.'s brain are fragmented and lacking in detail, so that they give rise to incomplete representations of, for example, public figures.

Phonemic cue	H.M.'s response	Phonemic cue	H.M.'s response
M.T.	Mao Tse-Tung	Woody A.	Woody Allen
Martin L. K.	Martin Luther King, Jr	Jimmy C.	Jimmy Carter
Bea	The Beatles	Henry Kiss	Henry Kissinger
L.B.J.	Lyndon B. Johnson	Gerald F.	Gerald Ford
Pablo P.	Pablo Picasso	Mother	Mother Theresa
Nelson Man	Nelson Mandela	Margaret Tha	Margaret Thatcher
Julie And	Julie Andrews	Nancy Rea	Nancy Reagan
Prince Ch	Prince Charles	G.B.	George Bush
Bob Dy	Bob Dylan	Michael Du	Michael Dukakis

and they didn't celebrate down there like they do up here — in the North. Like they don't have the trees or anything like that. And uh, but he came North even though he was born down Louisiana. And I know the name of the town he was born in." H.M. was unable to supply an episodic memory of his mother or his father — he could not narrate even one event that occurred at a specific time and place. In view of the lively disagreement about the participation of the hippocampus in memory consolidation and storage, it would be useful to know the status of H.M.'s pre-morbid semantic memory relative to his pre-morbid episodic memory. The 'standard' model of consolidation<sup>66–69</sup> predicts that remote episodic and semantic memory should be equivalent. By contrast, the multiple-trace theory<sup>65,70–73</sup> predicts a dissociation within remote memory such that autobiographical memory is the most

severely affected by MTL lesions, whereas memory for personal semantics, public events and famous people is less severely affected. Although our preliminary results

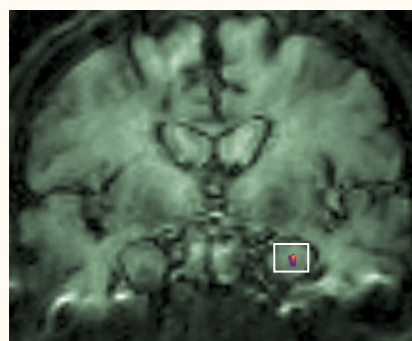
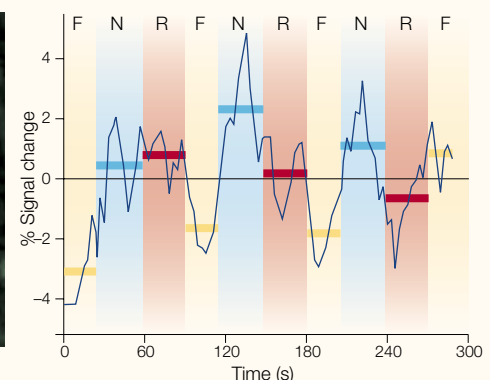


Figure 4 | Functional magnetic resonance imaging (fMRI) activation in H.M.'s caudal parahippocampal gyrus during novel picture encoding. Abbreviations: F, fixation; N, novel pictures; R, repeated pictures.

favour the latter view, a definitive answer awaits the results of more rigorous experiments that are now underway with H.M. and other amnesic patients.

Although H.M.'s remote memories do not contain as much detail as those of control participants, they do provide some fodder for his self-concept. Furthermore, beyond those fragmentary memories, he has beliefs, desires and values that are always present. For example, he believes that doing crossword puzzles helps him to remember words and is fun. He is altruistic: when I asked him to tell me about Dr Scoville (with whom H.M. had several appointments before his operation) he said, "He did medical research on people — all kinds of people. What he learned about me helped others too, and I'm glad about that." His social behaviour is appropriate and courteous. Years ago, when he and I were walking from the MIT Clinical Research Center to the Psychology Department, he would cup my elbow with his hand to guide me down the sidewalk. He has high moral standards with respect to right and wrong in his personal conduct, which is consistent with the preservation of his orbitofrontal cortex<sup>74</sup>. He has a conscience. For example, when explaining why he could not fulfil his dream of being a neurosurgeon, he cites the fact that he wears glasses, and that blood might spurt up onto his glasses, creating an obstacle to his vision and causing him to miss his target in the patient's brain, thereby causing the patient harm. In addition, he has good insight into his memory disorder. When I asked him, "What do you do to try to remember?" he replied, "Well, that I don't know 'cause I don't remember (laugh) what I tried." He has a sense of humour, and often makes jokes.

Another aspect of a sense of self is knowledge of one's appearance and physical state.



H.M. describes himself as 'thin but heavy.' He does not know his age, or whether he has grey hair. On one occasion when I showed him an old photograph of himself and his mother, he replied that the man looked like his father, but that it could not be his father because his father does not wear glasses. His ability to interpret and report internal states is diminished<sup>75</sup>. Specifically, he has an impaired ability to identify and respond to painful stimuli, and shows no difference in his ratings of hunger and thirst made before and after a meal.

A suggestion as to the neural substrate of self comes from Miller and colleagues<sup>76</sup>. They posit that the self comprises three cognitive domains (semantic knowledge, autobiographical memories and will), and that the first two are mediated by frontal lobe processes. Although knowledge of self is stored outside the frontal lobes, these structures are specialized for accessing, integrating and maintaining this information. Because H.M.'s frontal lobes are intact<sup>18</sup>, he has the substrate for organizing his meagre remote memories, perhaps to maintain a sense of self. Whether H.M. in fact has a sense of self is a matter for the reader to ponder.

#### When H.M. looks in the mirror

Students, scientists and lay people are fascinated by H.M.'s case history. When they hear about his condition, an abundance of questions follows. The most commonly asked question is: what happens when H.M. looks in the mirror? You could imagine that he might express shock and incredulity at the sight of an old man, because he does not remember that decades have elapsed since 1953 when his memory was last intact. I can report the following anecdotal evidence: when he looks at himself in a mirror, he shows no change in facial expression, his conversation is matter-of-fact, and he does not seem to be at all upset. On one occasion he was asked, "What do you think about how you look?" He replied, "I'm not a boy." This response reveals his sense of humour and his acceptance of the image he sees in the mirror. Although H.M.'s lack of concern might stem from his having had a bilateral amygdectomy, it could be the case that he actually perceives his face as familiar. This sense of familiarity would be the result of repeated daily exposure to his face year after year. The neural representation of his face is updated daily, probably in his intact fusiform face area, and perhaps through interactions with the posterior parahippocampal cortex (perirhinal cortex), which is believed to support familiarity discrimination<sup>29,60</sup>.

#### Prospects

H.M. is now 75 years old. His mobility is markedly reduced because of osteoporosis, another side effect of phenytoin (Dilantin). Although he is in relatively good health, plans are in place for the post-mortem examination of his brain when he dies. He and his court-appointed conservator have both signed his brain donation form, ensuring that the final chapter in his lifelong contribution to science will include a precise description of his brain and documentation of his lesion. His wish to help other people will have been fulfilled. Sadly, however, he will remain unaware of his fame and of the impact that his participation in research has had on scientific and medical communities internationally.

*Suzanne Corkin is at the Department of Brain and Cognitive Sciences and the Clinical Research Center, NE20-392, Massachusetts Institute of Technology, Cambridge, Massachusetts 02139, USA. e-mail: corkin@mit.edu*

DOI: 10.1038/nrn726

- Scoville, W. B. & Milner, B. Loss of recent memory after bilateral hippocampal lesions. *J. Neurol. Neurosurg. Psychiatry* **20**, 11–21 (1957).
- Eriksson, P. S. *et al.* Neurogenesis in the adult human hippocampus. *Nature Med.* **4**, 1313–1317 (1998).
- Penfield, W. & Milner, B. Memory deficit produced by bilateral lesions in the hippocampal zone. *AMA Arch. Neurol. Psychiatry* **79**, 475–497 (1958).
- Penfield, W. & Mathieson, G. Memory: autopsy findings and comments on the role of hippocampus in experiential recall. *Arch. Neurol.* **31**, 145–154 (1974).
- Milner, B., Corkin, S. & Teuber, H.-L. Further analysis of the hippocampal amnesic syndrome: 14-year follow-up study of H.M. *Neuropsychologia* **6**, 215–234 (1968).
- Corkin, S. Lasting consequences of bilateral medial temporal lobectomy: clinical course and experimental findings in H.M. *Semin. Neurol.* **4**, 249–259 (1984).
- Gabrieli, J. D. E., Cohen, N. J. & Corkin, S. The impaired learning of semantic knowledge following bilateral medial temporal-lobe resection. *Brain Cogn.* **7**, 157–177 (1988).
- Prisko, L.-H. *Short-Term Memory in Focal Cerebral Damage*. Thesis, McGill Univ., Montreal, Quebec, Canada (1963).
- Sidman, M., Stoddard, L. T. & Mohr, J. P. Some additional quantitative observations of immediate memory in a patient with bilateral hippocampal lesions. *Neuropsychologia* **6**, 245–254 (1968).
- Wickelgren, W. A. Sparing of short-term memory in an amnesic patient: implications for strength theory of memory. *Neuropsychologia* **6**, 235–244 (1968).
- Corkin, S. in *Alzheimer's Disease 19. A Report of Progress in Research* (eds Corkin, S., Davis, K. L., Growdon, J. H., Usdin, E. & Wurtman, R. J.) 149–164 (Raven, New York, 1982).
- Kensinger, E. A., Ullman, M. T. & Corkin, S. Bilateral medial temporal lobe damage does not affect lexical or grammatical processing: evidence from amnesic patient H.M. *Hippocampus* **11**, 337–346 (2001).
- Schmolck, H., Kensinger, E. A., Corkin, S. & Squire, L. R. Semantic knowledge in patient H.M. and other patients with bilateral medial and lateral temporal lobe lesions. *Hippocampus* **12** (in the press).
- MacKay, D. G., Burke, D. M. & Stewart, R. H.M.'s language production deficits: implications for relations between memory, semantic binding, and the hippocampal system. *J. Mem. Lang.* **38**, 28–69 (1998).
- MacKay, D. G., Stewart, R. & Burke, D. M. H.M. revisited: relations between language comprehension, memory, and the hippocampal system. *J. Cogn. Neurosci.* **10**, 377–394 (1998).
- MacKay, D. G. & James, L. E. The binding problem for syntax, semantics, and prosody: H.M.'s selective sentence-reading deficits under the theoretical-syndrome approach. *Lang. Cogn. Process.* **16**, 419–460 (2001).
- MacKay, D. G. A tale of two paradigms or metatheoretical approaches to cognitive neuropsychology. *Brain Lang.* **78**, 265–272 (2001).
- Corkin, S., Amaral, D. G., Johnson, K. A. & Hyman, B. T. H.M.'s medial temporal lobe lesion: findings from MRI. *J. Neurosci.* **17**, 3964–3979 (1997).
- Milner, B. in *Physiologie de l'Hippocampe* (ed. Passouant, P.) 257–272 (CNRS, Paris, 1962).
- Corkin, S. Acquisition of motor skill after bilateral medial temporal-lobe excision. *Neuropsychologia* **6**, 225–264 (1968).
- Shadmehr, R., Brandt, J. & Corkin, S. Time-dependent motor memory processes in amnesic subjects. *J. Neurophysiol.* **80**, 1590–1597 (1998).
- Gabrieli, J. D. E., Corkin, S., Mickel, S. F. & Growdon, J. H. Intact acquisition and long-term retention of mirror-tracing skill in Alzheimer's disease and in global amnesia. *Behav. Neurosci.* **107**, 899–910 (1993).
- Savoy, R. L. & Gabrieli, J. D. E. Normal McCollough effect in Alzheimer's disease and global amnesia. *Percept. Psychophys.* **49**, 448–455 (1991).
- Gabrieli, J. D. E., Merrill, F. D. & Corkin, S. Acquisition of perceptual skills in amnesia due to bilateral medial temporal-lobe (H.M.) or diencephalic lesions. *Soc. Neurosci. Abstr.* **12**, 20 (1986).
- Keane, M. M., Gabrieli, J. D. E., Mapstone, H. C., Johnson, K. A. & Corkin, S. Double dissociation of memory capacities after bilateral occipital-lobe or medial temporal-lobe lesions. *Brain* **118**, 1129–1148 (1995).
- Eichenbaum, H., Otto, T. & Cohen, N. J. Two functional components of the hippocampal memory system. *Behav. Brain Sci.* **17**, 449–518 (1994).
- Young, B. J., Otto, T., Fox, G. D. & Eichenbaum, H. Memory representation within the parahippocampal region. *J. Neurosci.* **17**, 5183–5195 (1997).
- Murray, E. A. & Mishkin, M. Object recognition and location memory in monkeys with excitotoxic lesions of the amygdala and hippocampus. *J. Neurosci.* **18**, 6568–6582 (1998).
- Aggleton, J. P. & Brown, M. W. Episodic memory, amnesia, and the hippocampal-anterior thalamic axis. *Behav. Brain Sci.* **22**, 425–489 (1999).
- Murray, E. A. in *The New Cognitive Neurosciences* (ed. Gazzaniga, M. S.) 753–763 (MIT Press, Cambridge, Massachusetts, 2000).
- Baxter, M. G. & Murray, E. A. Opposite relationship of hippocampal and rhinal cortex damage to delayed nonmatching-to-sample deficits in monkeys. *Hippocampus* **11**, 61–71 (2001).
- Ploner, C. J. *et al.* Spatial memory deficits in patients with lesions affecting the medial temporal neocortex. *Ann. Neurol.* **45**, 312–319 (1999).
- Ploner, C. J. *et al.* Lesions affecting the parahippocampal cortex yield spatial memory deficits in humans. *Cereb. Cortex* **10**, 1211–1216 (2000).
- Vargha-Khadem, F. *et al.* Differential effects of early hippocampal pathology on episodic and semantic memory. *Science* **277**, 376–380 (1997).
- McClelland, J. L., McNaughton, B. L. & O'Reilly, R. C. Why are there complementary learning systems in the hippocampus and neocortex: insights from the successes and failures of connectionist models of learning and memory. *Psychol. Rev.* **102**, 419–457 (1995).
- Teng, E. & Squire, L. R. Memory for places learned long ago is intact after hippocampal damage. *Nature* **400**, 675–677 (1999).
- Rosenbaum, R. S. *et al.* Remote spatial memory in an amnesic person with extensive bilateral hippocampal lesions. *Nature Neurosci.* **3**, 1044–1048 (2000).
- Maguire, E. A. & Cipolotti, L. Selective sparing of topographical memory. *J. Neurol. Neurosurg. Psychiatry* **65**, 903–909 (1998).
- O'Keefe, J. & Nadel, L. *The Hippocampus as a Cognitive Map* (Oxford Univ. Press, Oxford, 1978).
- Milner, B. Visually-guided maze learning in man: effects of bilateral hippocampal, bilateral frontal, and unilateral cerebral lesions. *Neuropsychologia* **3**, 317–338 (1965).
- Corkin, S. Tactually-guided maze learning in man: effects of unilateral cortical excisions and bilateral hippocampal lesions. *Neuropsychologia* **3**, 339–351 (1965).
- Landis, T., Cummings, J. L., Benson, D. F. & Palmer, E. P. Loss of topographical familiarity: an environmental agnosia. *Arch. Neurol.* **43**, 132–136 (1986).
- Habib, M. & Sirigu, A. Pure topographical disorientation: a definition and anatomical basis. *Cortex* **23**, 73–85 (1987).
- Obi, T., Bando, M., Takeda, K. & Sakuta, M. A case of topographical disturbance following a left medial parieto-occipital lobe infarction. *Rinsho Shinkeigaku* **32**, 426–429 (1992).

45. Maguire, E. A., Burke, T., Phillips, J. & Staunton, H. Topographical disorientation following unilateral temporal lobe lesions in humans. *Neuropsychologia* **34**, 993–1001 (1996).
46. Maguire, E. A. The retrosplenial contribution to human navigation: a review of lesion and neuroimaging findings. *Scand. J. Psychol.* **42**, 225–238 (2001).
47. Aguirre, G. K., Detre, J. A., Alsop, D. C. & D'Esposito, M. The parahippocampus subserves topographical learning in man. *Cereb. Cortex* **6**, 823–829 (1996).
48. Maguire, E. A., Frackowiak, R. S. J. & Frith, C. D. Learning to find your way — a role for the human hippocampal region. *Proc. R. Soc. Lond. B* **263**, 1745–1750 (1996).
49. Maguire, E. A. Hippocampal involvement in human topographical memory: evidence from functional imaging. *Phil. Trans. R. Soc. Lond. B* **352**, 1475–1480 (1997).
50. Maguire, E. A., Frackowiak, R. S. J. & Frith, C. D. Recalling routes around London: activation of the right hippocampus in taxi drivers. *J. Neurosci.* **17**, 7103–7110 (1997).
51. Maguire, E. A. *et al.* Knowing where and getting there: a human navigation network. *Science* **280**, 921–924 (1998).
52. McNaughton, B. L., Chen, L. L. & Markus, E. J. 'Dead reckoning', landmark learning, and the sense of direction: a neurophysiological and computational hypothesis. *J. Cogn. Neurosci.* **3**, 190–202 (1991).
53. Suzuki, W. A. & Amaral, D. G. Perirhinal and parahippocampal cortices of the macaque monkey: cortical afferents. *J. Comp. Neurol.* **350**, 497–533 (1994).
54. Bohbot, V. D. *et al.* Spatial memory deficits in patients with lesions to the right hippocampus and to the right parahippocampal cortex. *Neuropsychologia* **36**, 1217–1238 (1998).
55. Freed, D. M. & Corkin, S. Rate of forgetting in H.M.: 6-month recognition. *Behav. Neurosci.* **102**, 823–827 (1988).
56. Freed, D. M., Corkin, S. & Cohen, N. J. Forgetting in H.M.: a second look. *Neuropsychologia* **25**, 461–471 (1987).
57. Mandler, G. Recognizing: the judgment of previous occurrence. *Psychol. Rev.* **87**, 252–271 (1980).
58. Jacoby, L. L. & Dallas, M. On the relationship between autobiographical memory and perceptual learning. *J. Exp. Psychol. Gen.* **3**, 306–340 (1981).
59. Eldridge, L. L., Knowlton, B. J., Furlanski, C. S., Bookheimer, S. Y. & Engel, S. A. Remembering episodes: a selective role for the hippocampus during retrieval. *Nature Neurosci.* **3**, 1149–1152 (2000).
60. Brown, M. W. & Aggleton, J. P. Recognition memory: what are the roles of the perirhinal cortex and hippocampus? *Nature Rev. Neurosci.* **2**, 51–61 (2001).
61. Reed, J. M., Hamann, S. B., Stefanacci, L. & Squire, L. R. When amnesic patients perform well on recognition memory tests. *Behav. Neurosci.* **111**, 1163–1170 (1997).
62. Stern, C. E. *et al.* The hippocampal formation participates in novel picture encoding: evidence from functional magnetic resonance imaging. *Proc. Natl Acad. Sci. USA* **93**, 8660–8665 (1996).
63. Gabrieli, J. D. E., Brewer, J. B., Desmond, J. E. & Glover, G. H. Separate neural bases of two fundamental memory processes in the human medial-temporal lobe. *Science* **276**, 264–266 (1997).
64. Brewer, J. B., Zhao, Z., Glover, G. H. & Gabrieli, J. D. E. Making memories: brain activity that predicts whether visual experiences will be remembered or forgotten. *Science* **281**, 1185–1187 (1998).
65. Nadel, L., Samsonovich, A., Ryan, L. & Moscovitch, M. Multiple trace theory of human memory: computational, neuroimaging, and neuropsychological results. *Hippocampus* **10**, 352–368 (2000).
66. Zola-Morgan, S. & Squire, L. R. The primate hippocampal formation: evidence for a time-limited role in memory storage. *Science* **250**, 288–290 (1990).
67. Squire, L. R. & Zola-Morgan, S. The medial temporal lobe system. *Science* **253**, 1380–1386 (1991).
68. Squire, L. R. & Zola, S. Episodic memory, semantic memory, and amnesia. *Hippocampus* **8**, 205–211 (1998).
69. Squire, L. R., Clark, R. E. & Knowlton, B. J. Retrograde amnesia. *Hippocampus* **11**, 50–55 (2001).
70. Nadel, L. & Moscovitch, M. Memory consolidation, retrograde amnesia and the hippocampal complex. *Curr. Opin. Neurobiol.* **7**, 217–227 (1997).
71. Moscovitch, M. & Nadel, L. Consolidation and the hippocampal complex revisited: in defense of the multiple-trace model. *Curr. Opin. Neurobiol.* **8**, 297–300 (1998).
72. Fujii, T., Moscovitch, M. & Nadel, L. in *Handbook of Neuropsychology* (eds Bolter, F. & Grafman, J.) 223–250 (Elsevier, Amsterdam, 2000).
73. Nadel, L. & Bohbot, V. Consolidation of memory. *Hippocampus* **11**, 56–60 (2001).
74. Dolan, R. J. On the neurology of morals. *Nature Neurosci.* **2**, 927–935 (1999).
75. Hebben, N., Corkin, S., Eichenbaum, H. & Shedlack, K. Diminished ability to interpret and report internal states after bilateral medial temporal resection: case H.M. *Behav. Neurosci.* **99**, 1031–1039 (1985).
76. Miller, B. L. *et al.* Neuroanatomy of the self: evidence from patients with frontotemporal dementia. *Neurology* **57**, 817–821 (2001).
77. Gabrieli, J. D. E. *et al.* Dissociations among structural-perceptual, lexical-semantic, and event-fact memory systems in amnesia, Alzheimer's disease, and normal subjects. *Cortex* **30**, 75–103 (1994).
78. Graf, P., Squire, L. R. & Mandler, G. The information that amnesic patients do not forget. *J. Exp. Psychol. Learn. Mem. Cogn.* **10**, 164–178 (1984).
79. Diamond, R. & Rozin, P. Activation of existing memories in anterograde amnesia. *J. Abnorm. Psychol.* **93**, 98–105 (1984).
80. Shimamura, A. P. & Squire, L. R. Paired-associate learning and priming effects in amnesia: a neuropsychological study. *J. Exp. Psychol. Gen.* **113**, 556–570 (1984).
81. Postle, B. R. & Corkin, S. Impaired word-stem completion priming but intact perceptual identification priming with novel words: evidence from the amnesic patient H.M. *Neuropsychologia* **36**, 421–440 (1998).
82. Keane, M. M., Gabrieli, J. D. E., Growdon, J. H., Corkin, S. & Fennema, A. C. Evidence for a dissociation between perceptual and conceptual priming in Alzheimer's disease. *Behav. Neurosci.* **105**, 326–342 (1991).
83. Keane, M. M., Gabrieli, J. D. E., Growdon, J. H. & Corkin, S. Priming in perceptual identification of pseudowords is normal in Alzheimer's disease. *Neuropsychologia* **32**, 343–356 (1994).
84. Gabrieli, J. D. E., Fleischman, D. A., Keane, M. M., Reminger, S. L. & Morrell, F. Double dissociation between memory systems underlying explicit and implicit memory in the human brain. *Psychol. Sci.* **6**, 76–82 (1995).
85. Kensinger, E. A. & Corkin, S. Retrograde memory in amnesia: a famous faces study with the amnesic patient H.M. *Soc. Neurosci. Abstr.* **26**, 1241 (2000).
86. Mayes, A. *et al.* Two tests for assessing remote public knowledge: a tool for assessing retrograde amnesia. *Memory* **2**, 183–210 (1994).
87. Gabrieli, J. D. E., Milberg, W., Keane, M. M. & Corkin, S. Intact priming of patterns despite impaired memory. *Neuropsychologia* **28**, 417–427 (1990).
88. Keane, M. M., Gabrieli, J. D. E. & Corkin, S. Multiple relations between fact-learning and priming in global amnesia. *Soc. Neurosci. Abstr.* **13**, 1454 (1987).
89. Gabrieli, J. D. E., Cohen, N. J., Huff, F. J., Hodgson, J. & Corkin, S. Consequences of recent experience with forgotten words in amnesia. *Soc. Neurosci. Abstr.* **10**, 383 (1984).
90. Gabrieli, J. D. E., Keane, M. M. & Corkin, S. Computational goals of lexical-semantic priming: evidence from global amnesia. *Soc. Neurosci. Abstr.* **15**, 3 (1989).
91. Verfaellie, M., Gabrieli, J. D. E., Vaidya, C. J., Croce, P. & Reminger, S. L. Implicit memory for pictures in amnesia: role of etiology and priming task. *Neuropsychology* **10**, 517–528 (1996).
92. Gabrieli, J. D. E. *et al.* Behavioral and functional neuroimaging evidence for preserved conceptual implicit memory in global amnesia. *Soc. Neurosci. Abstr.* **22**, 1449 (1996).
93. Verfaellie, M., Cermak, L. S., Letourneau, L. & Zuffante, P. Repetition effects in a lexical decision task: the role of episodic memory in the performance of alcoholic Korsakoff patients. *Neuropsychologia* **29**, 641–657 (1991).
94. Scoville, W. B. The limbic lobe in man. *J. Neurosurg.* **11**, 64–66 (1954).
95. Eichenbaum, H., Morton, T. H., Potter, H. & Corkin, S. Selective olfactory deficits in case H.M. *Brain* **106**, 459–472 (1983).
96. Sagar, J. H., Cohen, N. J., Corkin, S. & Growdon, J. H. Dissociations among processes in remote memory. *Ann. NY Acad. Sci.* **444**, 533–535 (1985).
97. Hood, K. L., Postle, B. R. & Corkin, S. An evaluation of the concurrent discrimination task as a measure of habit learning: performance of amnesic subjects. *Neuropsychologia* **37**, 1375–1386 (1999).
98. Xu, Y. & Corkin, S. H.M. revisits the Tower of Hanoi Puzzle. *Neuropsychology* **15**, 69–79 (2001).

Acknowledgements

I thank B. Tickle for providing a computerized floor plan of his house; G. Papadimitriou, J. Van Meter and T. A. Zeffiro for the post-processing of H.M.'s MRI scan; and M. Keane, E. Kensinger, B. Milner, G. O'Kane and A. Wagner for commenting on earlier versions of this paper. I am grateful to the staff of the Massachusetts Institute of Technology (MIT) Clinical Research Center and the staff of H.M.'s nursing home for their excellent cooperation.

Online links

DATABASES

The following terms in this article are linked online to Medscape DrugInfo:

<http://promini.medscape.com/drugdb/>

Dilantin

OMIM: <http://www.ncbi.nlm.nih.gov/Omim/>

epilepsy

FURTHER INFORMATION

Encyclopedia of Life Sciences: <http://www.els.net/>

amnesia | hippocampus | learning and memory | memory: clinical disorders

MIT Encyclopedia of Cognitive Sciences:

<http://cognet.mit.edu/MITECS/>

hippocampus | memory | memory, human neuropsychology | memory storage, modulation of

Access to this interactive links box is free online.